

COMPUTED TOMOGRAPHY CHARACTERISTICS OF ACUTE TRAUMATIC EPIDURAL HEMATOMA IN SURGICALLY TREATED PATIENTS AT MILITARY HOSPITAL 103

Tran Anh Duc^{1*}, Nguyen Thanh Bac¹

ABSTRACT

Objectives: To describe the computed tomography characteristics of acute traumatic epidural hematoma in surgically treated patients.

Subjects and methods: A cross-sectional descriptive study was conducted in 68 patients diagnosed with traumatic epidural hematoma who underwent surgery at the Department of Neurosurgery, Military Hospital 103, from January 2024 to June 2025. Computed tomography characteristics were evaluated, including hematoma location, density, volume, degree of midline shift, and skull injury.

Results: Among 68 surgically treated patients, 85.3% were male and the mean age was 34.5 ± 15.6 years. Unilateral hematoma was seen in 97.1% of cases, most commonly in the temporal region (39.7%), followed by multilobar distribution (19.1%). Hyperdense hematoma was the predominant CT finding (85.3%), while 14.7% had mixed density. Hematoma volume was mainly 30–60 mL (47.1%), and 36.8% of patients had midline shift < 5 mm, whereas 10.3% had shift > 10 mm. Skull fracture was present in 92.6% of cases.

Conclusions: On computed tomography, acute traumatic epidural hematoma commonly appears as a hyperdense lesion, usually located in the temporal region, and may be associated with midline shift.

Keywords: Traumatic epidural hematoma, computed tomography, Military Hospital 103.

Corresponding author: Tran Anh Duc, Email: tranhanhducvmmu@gmail.com

Received: 11/02/2026; scientific review: 02/2026; accepted:

¹Military Hospital 103.

1. INTRODUCTION

Epidural hematoma (EDH) is a common form of intracranial hemorrhage following traumatic brain injury (TBI), with a significant proportion posing a life-threatening risk to patients and requiring urgent neurosurgical intervention [1]. EDH accounts for 1–20% of all TBI cases and approximately 5–15% of severe TBI cases [2]. Although some cases of EDH may be managed conservatively, early recognition of clinical manifestations, disease progression, and diagnostic criteria is critical for timely surgical decision-making, in order to limit hematoma expansion, reduce intracranial pressure, and minimize the risk to life. Non-contrast computed tomography (CT) is the primary imaging modality for detecting the majority of EDH cases. Moreover, accurate identification of characteristic CT findings facilitates differentiation of EDH from other types of intracranial hemorrhage. Therefore, systematic evaluation of CT imaging characteristics is of significant importance for the diagnosis, prognosis, and surgical planning in

patients with acute traumatic EDH. In Vietnam, studies systematically describing CT imaging characteristics-particularly in the surgical patient population-remain limited.

Military Hospital 103 is a major referral and treatment center for TBI patients, in which EDH constitutes a common neurosurgical emergency requiring rapid CT evaluation. Based on this clinical context, the present study was conducted to describe the CT imaging characteristics of acute traumatic EDH in patients with surgical indications at Military Hospital 103.

2. SUBJECTS AND METHODS

2.1. Subjects

68 patients diagnosed with acute traumatic EDH who underwent surgical treatment at the Department of Neurosurgery, Military Hospital 103, from January 2024 to June 2025.

Exclusion criteria: patients with non-traumatic EDH or traumatic EDH managed non-operatively;

patients with insufficient data or who declined to participate.

2.2. Methods

- Study design: cross-sectional descriptive study, evaluating CT imaging characteristics in patients with acute traumatic EDH.

- Sampling method: convenience sampling; all patients meeting inclusion criteria and not meeting exclusion criteria during the study period were enrolled.

- Research procedures: eligible patients were enrolled; data on age, sex, and non-contrast cranial CT scans were collected using a standardized data collection form; CT imaging characteristics evaluated included hematoma location, density, volume, degree of midline shift, and skull injury status.

- Study variables:

+ Patient characteristics: age, sex.

+ Hematoma location by cerebral hemisphere: unilateral, bilateral.

+ Hematoma location: frontal, parietal, occipital, temporal, multilobar, bilateral hemispheres.

+ Hematoma CT density: hyperdense, hypodense, mixed density.

+ Hematoma volume on non-contrast CT, estimated using the formula:

$$V = (A \times B \times C)/2 \text{ (mm}^3\text{)}.$$

Where A is the maximum diameter of the hematoma on the slice with the largest area; B is the diameter perpendicular to A on the same slice; C is the estimated height of the hematoma, calculated as the number of slices containing hematoma multiplied by the slice thickness (mm). Values were converted from mm³ to mL according to the software/measurement unit convention. EDH volume was categorized as: 30-60 mL, 61-90 mL, and > 90 mL.

+ Degree of midline shift on CT: no shift, < 5 mm, 5-10 mm, and > 10 mm.

+ Skull injury status: present or absent.

- CT image reading and hematoma volume measurement were performed independently by two specialist physicians using a standardized data collection form. In cases of discrepancy, a consensus was reached through discussion or consultation with a third physician.

- Ethics: the study was reviewed and approved by Military Hospital 103. Data collection was

performed after obtaining informed consent from patients or their legal representatives; data were anonymized, kept confidential, and used solely for research purposes.

- Statistical analysis: data were processed using Microsoft Excel and SPSS 26.0. Descriptive statistical methods were applied.

3. RESULTS

- Patient age and sex characteristics:

+ Age: patients ranged from 11 to 70 years, with a mean age of 34.5 ± 15.6 years.

+ Sex: 58 patients (85.3%) were male and 10 patients (14.7%) were female.

- Hematoma location by cerebral hemisphere:

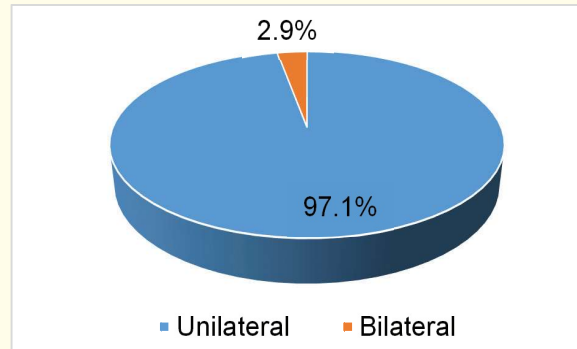


Figure. Hematoma distribution by cerebral hemisphere.

66 of 68 patients (97.1%) had a unilateral hematoma, and only 2 patients (2.9%) had bilateral hematomas.

Table 1. Hematoma location characteristics

Hematoma location	No. of patients	Proportion (%)
Frontal region	9	13.2
Parietal region	11	16.2
Temporal region	27	39.7
Occipital region	6	8.8
Multilobar	13	19.1
Bilateral hemispheres	2	2.9
Total	68	100

The most common hematoma location was the temporal region (39.7%), followed by multilobar distribution (19.1%), parietal region (16.2%), and frontal region (13.2%); bilateral hemispheric hematomas were the least common (2.9%).

Table 2. CT density characteristics of the hematoma

CT density	No. of patients	Proportion (%)
Hyperdense	58	85.3
Hypodense	0	00.0
Mixed density	10	14.7
Total	68	100

The majority of patients had a hyperdense hematoma (85.3%); only 14.7% had a mixed-density hematoma with swirl sign on CT.

Table 3. Hematoma volume characteristics

Hematoma volume	No. of patients	Proportion (%)
30-60 mL	32	47.1
61-90 mL	24	35.3
> 90 mL	12	17.6
Total	68	100

Hematoma volume of 30-60 mL was most common (47.1%), followed by 61-90 mL (35.3%) and > 90 mL (17.6%).

Table 4. Midline shift characteristics

Midline shift	No. of patients	Proportion (%)
No shift	19	27.9
< 5 mm	25	36.8
5–10 mm	17	25.0
> 10 mm	7	10.3
Total	68	100

A large proportion of patients had no midline shift (27.9%) or midline shift < 5 mm (36.8%). Only 10.3% of patients had midline shift > 10 mm.

Table 5. Skull fracture characteristics

Skull fracture	No. of patients	Proportion (%)
Present	63	92.6
Absent	5	7.4
Total	68	100

The majority of patients had skull fracture (92.6%). Only 7.4% of patients had no skull fracture.

4. DISCUSSION

Acute traumatic EDH has characteristic CT imaging findings, typically presenting as a biconvex (lens-shaped) hyperdense mass, with one convex surface against the inner skull table and the

other convex surface caused by the hematoma compressing the dura mater [3]. The bleeding source originates from traumatically injured arterial or venous vessels, with blood accumulating between the dura mater and the inner skull table. The CT appearance differs from other intracranial hemorrhage types, such as subdural hematoma, intracerebral hematoma, or subarachnoid hemorrhage. Regarding hematoma location, this study found that the majority of hematomas were located in the temporal lobe (39.7%), followed by multilobar distribution (19.1%). Multilobar hematomas were those located at the junction between lobes (temporoparieto-occipital, temporo-occipital, fronto-temporal regions, etc.). Two patients (2.9%) had hematomas in different cerebral hemispheres. These findings are consistent with the study by Nguyen Thanh Thao [4] (the most common hematoma location was the temporal lobe, accounting for 53.8%).

The majority of patients had a hyperdense hematoma (85.3%) - a characteristic finding of acute EDH. This finding is consistent with the study by Nguyen Thanh Thao [4] (the majority of patients had hyperdensity on CT). 14.7% of patients had a mixed-density hematoma with swirl sign on CT - a finding indicative of active bleeding at the time of imaging and the potential for hematoma volume expansion. The swirl sign on CT is considered a marker of active hemorrhage and has been associated with a higher risk of adverse postoperative outcomes [5], [6]. Therefore, patients with the swirl sign require close neurological monitoring and should be prioritized for early intervention.

Table 3 shows that the predominant hematoma volume was 30-60 mL (47.1%), followed by 61-90 mL (35.3%), with only 17.6% of patients having a hematoma volume > 90 mL. This finding differs from the study by Nguyen Thanh Thao [4] (76% of EDH had a volume < 30 mL). This discrepancy is explained by the fact that the present study included only patients with surgical indications, whereas the study by Nguyen Thanh Thao included all EDH patients regardless of management. Our findings are consistent with those of Lobato [7] (58% of hematomas had a volume of 20-60 mL).

The degree of midline shift is an important CT imaging characteristic in TBI patients. In the present study, 36.8% of patients had midline shift < 5 mm, 35.3% had midline shift \geq 5 mm (including 10.3% with midline shift > 10 mm), and 19 patients (27.9%) had no midline shift attributable to the hematoma. Midline shift in acute EDH results from the large hematoma volume compressing adjacent brain parenchyma, or from cerebral edema secondary

to infarction in patients with large hematomas, displacing the midline toward the contralateral side. Our findings are consistent with those of Nguyen Thanh Thao [4] (30.8% of patients had midline shift ≥ 5 mm), and Lobato [7] (40% of patients had midline shift < 4 mm). In the literature, hematoma volume and degree of midline shift are imaging factors associated with functional outcome [8]. In clinical practice, hematoma volume and midline shift are important indicators for assessing the degree of mass effect and guiding management decisions. According to current guidelines, EDH > 30 cm³ constitutes a surgical indication for hematoma evacuation, whereas EDH < 30 cm³ with thickness < 15 mm and midline shift < 5 mm in neurologically stable patients may be considered for conservative management with close neurological and CT monitoring. As this study included only surgically managed patients, the distribution of hematoma volume and/or midline shift was skewed toward the more severe end, which is consistent with the study sampling criteria.

In addition to the above findings, skull fracture is also a common finding in TBI. Table 5 shows that the majority of patients had skull fracture (92.6%), with only 5 patients (7.4%) having no skull fracture. Skull fracture is one of the leading causes of EDH. Various types of skull fracture may occur, including linear, depressed, comminuted, or diastatic suture fractures. Nevertheless, some patients may develop EDH without associated skull fracture. In such cases, the source of bleeding is primarily attributed to injury of meningeal vessels.

Study limitations: this study was conducted at a single center and included only surgically treated patients. Therefore, selection bias may exist, and the results may not fully reflect the CT characteristics of all EDH patients (including those managed conservatively). Hematoma volume estimated using the ABC/2 formula is a simplified method that may introduce some inaccuracy for irregularly shaped hematomas. The cross-sectional descriptive design limits the ability to infer causal relationships.

5. CONCLUSION

A study of CT imaging characteristics in 68 patients with traumatic epidural hematoma who underwent surgical treatment at the Department of Neurosurgery, Military Hospital 103, found that the majority of patients had a unilateral hematoma (97.1%), predominantly located in the temporal lobe (39.7%), with hyperdense appearance on CT (85.3%), hematoma volume of 30–60 mL (47.1%), midline shift < 5 mm (36.8%), and skull fracture (92.6%).

REFERENCES

1. Goubert R, Wray A, Matonis D, “A Case Report of Epidural Hematoma After Traumatic Brain Injury”, *J Educ Teach Emerg Med*, 15 (3): V22-V24, 2020.
2. Sengkhamyong Kingkeo, *Diagnosis and evaluation of surgical treatment outcomes of acute supratentorial traumatic epidural hematoma*, Doctoral Dissertation in Medicine, Vietnam Military Medical University, 2012.
3. Bullock M Ross, Chesnut Randall, Ghajar Jamshid, *et al.*, “Surgical management of acute epidural hematomas”, *Neurosurgery*, 58(3 Suppl): S2-S7, 2006.
4. Nguyen Thanh Thao, “Computed tomography imaging characteristics of acute epidural hematoma in traumatic brain injury”, *Journal of Medicine and Pharmacy, Hue University of Medicine and Pharmacy*, 2(11): pp. 91-95, 2021.
5. Guo Cheng, Liu Lin, Wang Bing, *et al.*, “Swirl sign in traumatic acute epidural hematoma: prognostic value and surgical management”, *Neurological Sciences*, 38(12): pp. 2111-2116, 2017.
6. Chen Hao, Guo Yan, Chen Shi-Wen, *et al.*, “Progressive epidural hematoma in patients with head trauma: incidence, outcome, and risk factors”, *Emergency medicine international*, 2012(1): 134905, 2012.
7. Lobato RD, Rivas J.J, Cordobes F, *et al.*, “Acute epidural hematoma: an analysis of factors influencing the outcome of patients undergoing surgery in coma”, *J Neurosurg*, 68(1): pp. 48-57, 1988.
8. Lee EJ, Hung YC, Wang LC, *et al.*, Factors influencing the functional outcome of patients with acute epidural hematomas: analysis of 200 patients undergoing surgery. *Journal of Trauma and Acute Care Surgery*, 45(5), pp. 946-952, 1998. □